

Clinical case

Implant-prosthetic dental rehabilitation after autopolytrauma

Vladimir Put^{1,2}, Dmitry Usatov¹, Dmitry Svyatoslavov¹, Alexander Dolgalev³, Mikhail Gladyshev², Evgeny Basin⁴, Victoria Polshina¹, David Choniashvili⁵, Artur Chagarov³, Vazgen Avanisyan⁶, Daniil Gordeev^{7, 8,*}, Valentin Popadyuk⁷, Igor Ganshin⁸

- ¹ Department of Oncology radiology and plastic surgery of the First MSMU. I. M. Sechenova of the Ministry of HealthCare of the Russian Federation (Sechenov University), 119991, Russian Federation.
- ² Department of oral rehabilitation of the Private Educational Institution of Higher Professional Education Moscow Witte University, 115432, Russian Federation.
- ³ Department of General Practice Dentistry and Pediatric Dentistry, Stavropol State Medical University, 355017, Russian Federation.
- ⁴ Department of Oncology and plastic surgery, Postgraduate Academy of Education FGBU FNKC FMBA, 125371, Russian Federation.
- ⁵ Department of Therapeutic, Surgical and Pediatric Dentistry with a Course of Implantology, Reconstructive Oral Surgery, Pediatric Dentistry Federal, State Budgetary Educational University of Higher Education North Ossetian State University named after Kosta Levanovich Khetagurov (NOSU), 362025, Russian Federation.
- ⁶ Department of Therapeutic Dentistry, Stavropol State Medical University, 355017, Russian Federation.
- ⁷ Department of Otorhinolaryngology of the Peoples Friendship University of Russia (RUDN University), 117198, Russian Federation.
- ⁸ Department of Plastic Surgery of the Peoples Friendship University of Russia (RUDN University), 117198, Russian Federation.

* Correspondence: dr.danila@yandex.ru; Tel.: +916 3681230
 pout-prof@mail.ru, <https://orcid.org/0000-00034150-9885> (V.P.)
 usatovdm@mail.ru, <https://orcid.org/0000-0002-8171-5002> (D.U.)
 dolgalev@dolgalev.pro, <https://orcid.org/0000-0002-6352-6750> (D.S.)
 dssvyatoslavov78@mail.ru, <https://orcid.org/0000-0003-0898-8693> (A.D.)
 gladent@mail.ru, <https://orcid.org/0000-0002-5330-3369> (M.G.)
 dr.basin@mail.ru, <https://orcid.org/0000-0003-1931-8062> (E.B.)
 vi.polshina@gmail.com, <https://orcid.org/0000-0001-5750-2093> (Vi.P.)
 davidchoniashvili@mail.ru, <https://orcid.org/0000-0003-4218-1359> (D.C.)
 megalowin188@mail.ru, <https://orcid.org/0000-0003-4625-6266> (A.C.)
 avanvaz@yandex.ru, <https://orcid.org/0000-0002-0316-5957> (V.A.)
 dr.danila@yandex.ru, <https://orcid.org/0000-0003-3322-5380> (D.G.)
 ikastyro@gmail.com, <https://orcid.org/0000-0001-6134-3080> (I.K.)
 lorval04@mail.ru, <https://orcid.org/0000-0003-3309-4683> (Val.P.)
 gibdoc@yandex.ru, <https://orcid.org/0000-0001-5766-9416> (I.G.)

Citation: Put V., Usatov D., Svyatoslavov D., Dolgalev A., Gladyshev M., Basin E., Polshina V., Choniashvili D., Chagarov A., Avanisyan V., Gordeev D., Popadyuk V., Ganshin I. Implant-prosthetic dental rehabilitation after autopolytrauma. Journal of Clinical Physiology and Pathology (JCPP) 2023; 1 (1): 11-18.

<https://doi.org/JCPP.2023-2-1.11-18>

Academic Editor: Igor Kastyro

Received: 01.02.2023

Accepted: 25.02.2023

Published: 01.03.2023

Publisher's Note: International Society for Clinical Physiology and Pathology (ISCPP) stays neutral with regard to jurisdictional claims in published maps and institutional affiliations.

Copyright: © 2023 by the authors. Submitted for possible open access publication.

Abstract: With extensive damage of the facial skeleton, multiple bony and soft tissue cicatricial defects and deformations are formed. Traditional methods of reconstructive are reliably not able to restore the defects fully. Often the bony structures of the facial skeleton can't be restored in one stage. Additional reconstructive surgeries are needed. A problematic situation is the condition after multiple surgeries in the defect area. Failure of bone grafting is associated with cicatricial deformities and lack of soft tissue, lack of gingiva, defects in the vestibule and damaged periosteum. The main problem is constriction and subsequent atrophy and deformation of the soft tissue in the area of the defect. This complicates further treatment and often it isn't possible to restore the bone volume required for a successful dental implantation. Implant prosthetic rehabilitation in the area of extensive bone defects after a facial injury requires preparation that is more careful, design and prototyping of the outcome with the use of computer programs and diagnostic models. Biocompatible materials for dentistry and maxillofacial surgery are clinically proven and recommended for usage in patients at the treatment stages. Clinical experience with individual temporary endoprosthesis, so called "tissue expander", produced by layer-by-layer synthesis (3D-printing) from biologically inert plastic based on CT data of the patient is presented in this article. The expander is made in the form of a 3D element to form the required soft tissue volume in the patient for 4-6 months and is fixed in place subcutaneously, in the area of mandibular frontal defect, using intraosseous screws. Dental implants were placed laterally on both sides. The following was carried out intraoperative direct replacement, fabrication and placement in the mouth of a temporary screw-retained prosthesis.



Keywords: facial trauma; fracture; maxillofacial defect; soft tissue constriction; endoprosthesis; autosseous plasty of the jaw; dental implantation.

1. Introduction

The question regarding the search for the optimal method of defect reconstruction and restoration of the integrity of the skull and facial skeleton remains topical. The works devoted to the study of the possibility of facial skeleton reconstruction by free bone autografts with one-stage or subsequent dental implantation are of interest [1,2]. The possibility of obtaining significant amounts of autologous material is very limited, and the donor is usually subjected to serious surgical interventions during its harvesting. The most important in autologous bone grafting is the recipient area, especially after significant traumatic injuries [2,3,13,15]. Violations of bone grafting protocols and lack of soft tissues can lead to autologous bone blocks eruption, suture discrepancy, and loss of the graft. The key factor of success is the work with tissue flaps and their passive positioning. With significant bony defects of the face and jaws, the soft tissues are deformed and not always sufficient to cover the flap. The possibilities of preliminary volume augmentation and quality of soft tissues in the area of the bone defect are studied [4,16]. Tissue silicone expanders have been used in oral surgery for quite a long time, but the result is not always stable [3]. 3D-printing of bioinert materials is actively being introduced in bone surgery [6,7,18]. Positive experience has been accumulated in the use of bioinert plastic and composite materials objects (experimental animals) [8,17]. In addition, the most important criterion is the possibility of protecting the augmentation area in the clinic of dentistry and maxillofacial surgery with temporary prosthetic constructions. This will improve healing and is a prevention of suture divergence [9,14]. Important criteria are treatment time and its reduction and the quality of life of the patient, especially for interventions in the frontal zone of the jaws [10]. We present clinical experience with the use of an individual temporary endoprosthesis, the so-called "tissue expander", manufactured using additive technologies (3D-printing). The expander was fabricated by layer-by-layer synthesis from a biologically inert plastic to form the required soft tissue volume for a period of four-six months. In a clinical example the possibilities of 3D-printing as a creation of an individual temporary endoprosthesis were realized, which allowed to increase the quality of surgical intervention and optimize conditions for subsequent autologous bone grafting and successful implantation in the area of the defect. In addition, the possibility of dental implants installation in the area of the defect and making a temporary screw prosthesis in the shortest possible time was realized [11,12]. All this has shortened the treatment period and improved the patient's quality of life.

2. Patients and Methods

The anamnesis data established: auto polytrauma, with extensive damage to the facial skeleton bones in April 2021. On April 30, 2021, he was delivered from the accident site to Sochi Hospital with complaints of asymmetry and pains in the facial area, disorder of teeth occlusion. Allied specialists examined the patient. Final diagnosis was closed craniocerebral injury. The patient had a concussion of the brain, bilateral fracture of the zygomatic-orbital complex. Fracture of the upper jaw in the type of Le Fore 2-3. Fracture of the lower jaw in the frontal region. Bone defect in the region of teeth 3.4 - 4.3. ICD 10 S02.7. On admission: general condition is severe. Internal organs were within the physiological norm. Locally: the configuration of the face was changed due to post-traumatic edema in all areas of the face. Infraorbital hematomas were on the right and left side. Lacerations of the lower lip was on the left side, 10 cm long. Oral side: skeletonized lower jaw in the area of missing teeth 3.4 - 4.3, also pathological mobility of the jaw. The bite is displaced and was classified as open bite.

Surgical treatment. Repositioning, metal osteosynthesis of the upper and lower jaws, zygomatic-orbital complex with titanium plates. Intermaxillary splinting was made according to Tigerstedt. Primary surgical treatment and suturing of wounds were done. The patient underwent a course of anti-inflammatory therapy. The mouth opened within 20 mm. The patient was discharged under the supervision of a dental surgeon at the place of residence. On May 14, 2021 in Krasnodar, the patient underwent additional treatment of metal osteosynthesis of zygomatic-orbital complexes. The cause of the complaint was deformity of the zygomatic-orbital regions and recurrent diplopia. It was recommended: to solve the problem of the possibility to eliminate the bone defect in the frontal part of the alveolar part of the lower jaw - augmentation with the purpose of further implantation and prosthetics.

The patient was admitted to the University Clinical Hospital № 1 of the First Moscow State Medical University named after I.M. Sechenov in March 2022. Facial skeleton CT: extensive defect in the alveolar part of the lower jaw in the area of missing 3.4 - 4.3 teeth (Fig. 1).



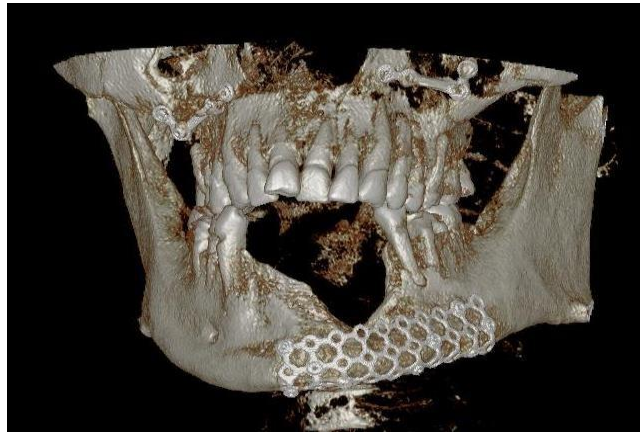


Figure 1. Screenshot of a 3D CT scan of the maxillary alveolar defect of the mandible.

Complaints: absence of teeth on the lower jaw in the frontal aspect, functional and aesthetic discomfort, difficulty in chewing and difficulties in eating and speaking.

The patient is a doctor by occupation. During the planning stage of the surgery, the following activities were performed:

- polymeric models of expanders and jaws were investigated,
- the size, insertion path, and fixation zones of an individual temporary endoprosthesis (tissue expander) are coordinated
- size and number of screws for fixation
- the directions and channels in the endoprosthesis for inserting screws are set in the software package.

Planned Intervention:

1. Design and prototyping of the intervention on 3D-models, coordination of size, shape, insertion path, and points of fixation of an individual endoprosthesis-expander
2. Removal of the metal structure.
3. Dental implantation in the lower jaw area. Dental implantation in the lower jaw area of teeth 35,36 removed and 42,43
4. Installation of an individual endoprosthesis-expander in the region of the lower jaw in the frontal part of the lower jaw-area of the defect.
5. CAD/CAM fabrication of a temporary implant-supported screw-retained prosthesis

We made prototypes for planning the surgery - samples of expanders and jaw models, coordinated the size, the path of insertion and fixation zones of the endoprosthesis, the size and number of screws for fixation (Fig. 2)

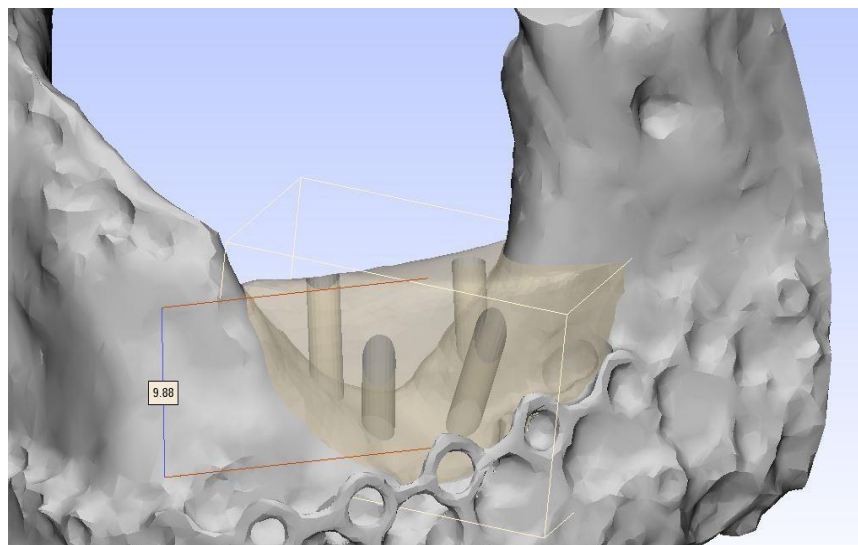


Figure 2. Digital 3D-modeling of the endoprosthesis.



Mock-ups of the jaw and expanders were made:

- Additive technology: SLS (selective laser sintering) - layer-by-layer fusion of polymer powder with a laser beam. The jaw model is also quite adequately obtained by FDM-printing (fusing deposition modeling) - layer-by-layer extrusion of polymer thread (filament), for example, from polycarbonate or ABS plastic.
- Expander fixation was planned with titanium screws to the body of the jaw. sizes 1.5-12 mm
- Equipment for making layouts: additive unit EOSINT, EOS company (Germany)
- Layout materials: biocompatible polymer powder polyamide 12 (PA2200) (Fig. 3).

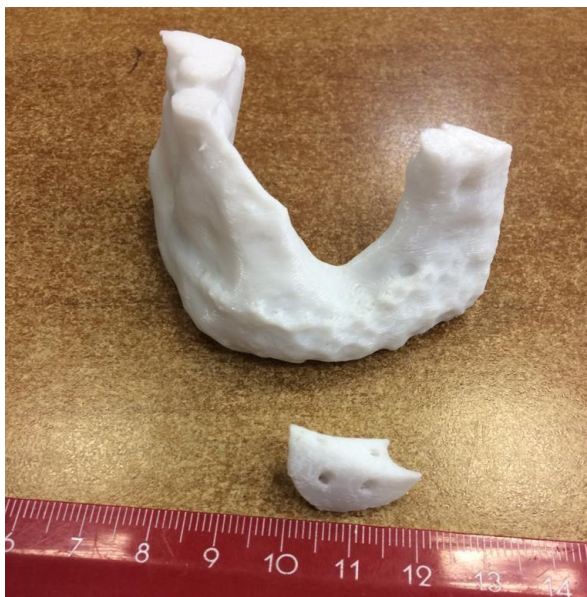

Figure 3. Mock-ups of the jaw and endoprosthesis-expander.

Under endotracheal anesthesia and local anesthesia with 4% articaine the mucosal-periosteal flap was detached. When making the incision, it was important to preserve the keratinized area of the attached gingiva in the implant area. The mesh metal construction in the frontal area of the lower jaw region was removed (Fig. 4).

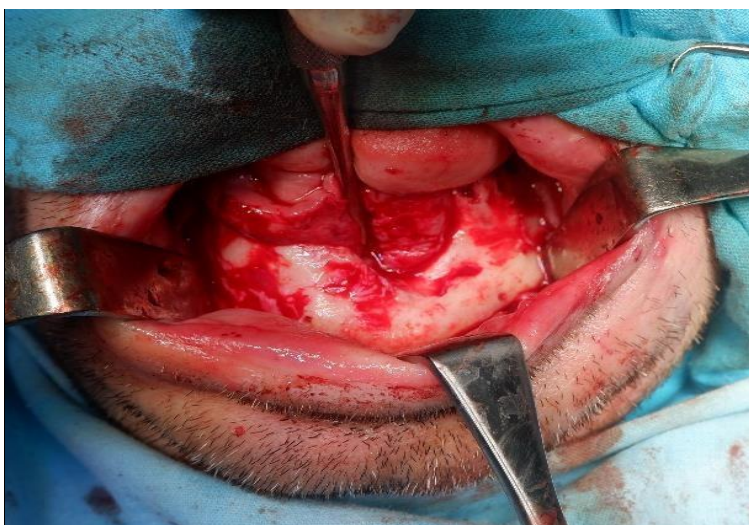

Figure 4. Skeletonized lower jaw, removed titanium plate, appearance of the defect.



Teeth 35, 36 were extracted, dental implants were placed in the cavity of tooth 35, anterior root of tooth 36 and 42, 43. Pterygoid I-implant BioLine implants with next coming measures: 36 - 3/75-18 mm 35 - 4/2 -20, 42 - 4.2-22 and 43 - 4.2/22 mm, respectively, were placed into the dental sockets.

Conical screw abutments with a neck height of two mm were placed in the implants and covered with protective caps. The individual temporary endoprosthesis, "tissue expander", was fixed subcutaneously, in the area of the mandibular frontal defect with intraosseous screws 1.5 mm-12 mm (Fig. 5).

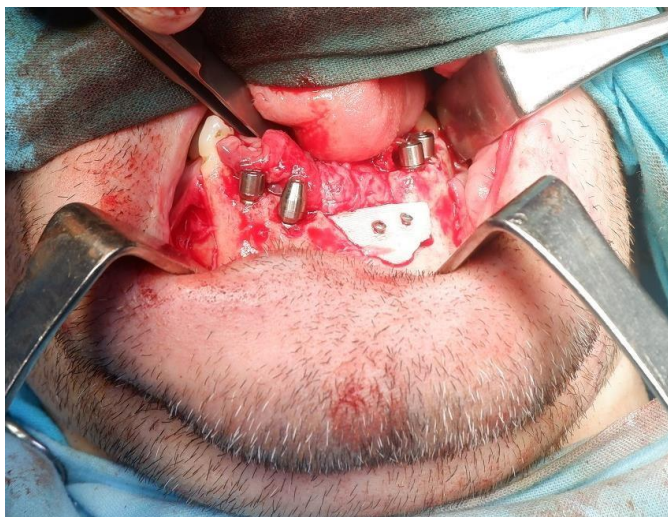

Figure 5. Implants, screw abutments and caps were placed, and the endoprosthesis was fixed.

Resorbable 5.0 Monisin Resorba sutures were stithed. Intraoperatively, impressions were taken using a custom-made spoon and transfer-checks. The bite was determined. Temporary screw dentures were made in the dental laboratory in 24 hours by CNC milling from PMMA polymer composite (Fig. 6).

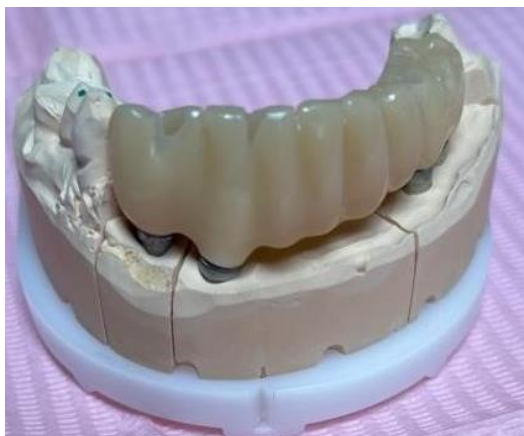

Figure 6. PMMA bridge, which was made by milling.

Direct intraoperative prosthetics was performed, the prosthesis was placed in the oral cavity, fixed with M1.4 screws to the abutments. The wells of the screws were sealed with A-silicone (Fig. 7). Control radiological diagnostics was carried out (Fig. 8).



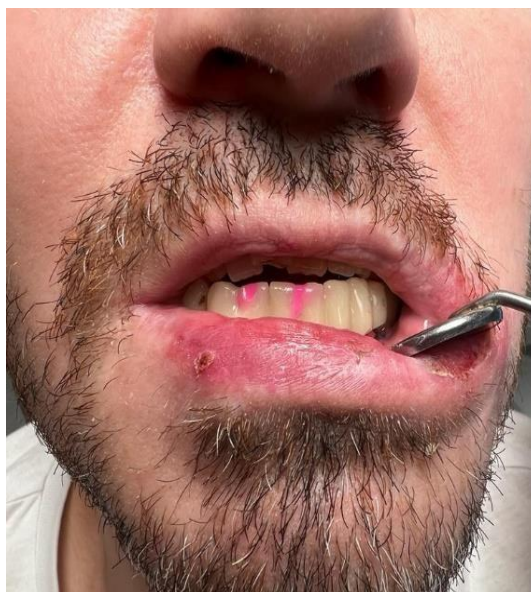

Figure 7. View of a patient with a prosthesis in the oral cavity.

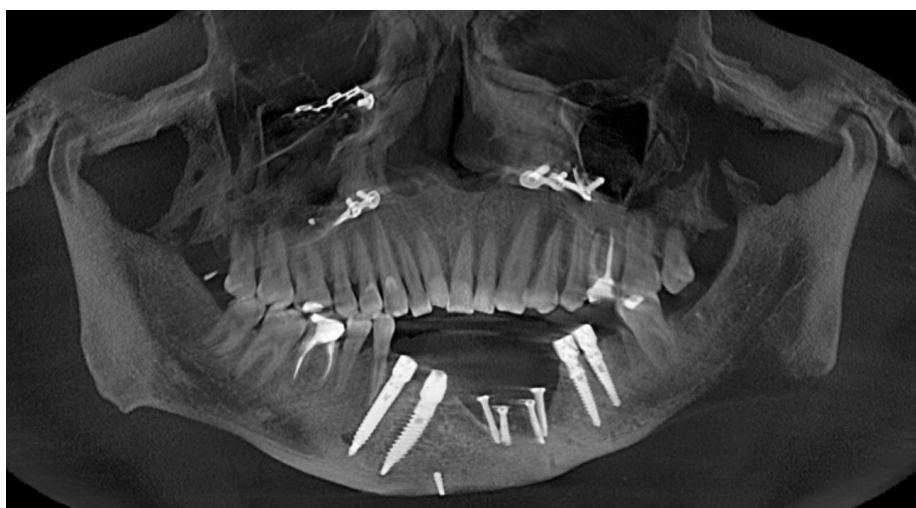


Figure 8. Control CT-scan after surgery, implants and expander have been placed.

The patient was referred for rehabilitation. In 5 months, the patient is scheduled to have the expander removed, autologous bone grafting with bone chips in height, and placement of two implants in the defect area.

3. Results

At the stage of surgical intervention, the main difficulties arose in the removal of the reticular metalwork in the frontal area of the lower jaw. Tooth extraction had to be carried out as atraumatically as possible. During the implants placing, a previously fabricated polymer template was used. This allowed to place the implants in the most correct position for the fabrication of prosthesis, taking into account the significant deformation of the upper and lower jaws. Individual temporary polymeric endoprosthesis, fixed in the area of frontal defect of lower jaw with intraosseous screws with significant compression. After slight immobilization, the flap was passively placed and sutured. No clinical manifestations were detected in the area of the endoprosthesis. A significant reduction of more than four mm in height of the intermediate part of the temporary screw bridge was required due to an increase in the tissue level in the area of the installed expander. The patient noted high quality of life, restoration of chewing function and aesthetics. Referred for rehabilitation in Sochi. After six months, removal of the tissue expander, autologous bone grafting, and placement of two implants in the area of the defect is planned.



Orthodontic treatment on the upper jaw is also recommended. According to the data provided by the dentists observing the patient, there were no clinical manifestations in the area of the endoprosthesis during the period from the operation to September 2022.

4. Discussion

A progressive trend in maxillofacial and bone surgery is the possibility of personalizing implant prosthetic structures [13-16]. Application of additive technologies for manufacturing individual maxillofacial implants makes it possible to design and prototype complex solutions on models, optimize prosthesis fixation systems taking into account elasticity modulus and bone density. The size and configuration of the "prosthetic body of fixation elements and orthopedic platforms" is determined by the attending physician or the consensus of specialists. The parameters for the necessary angulation of orthopedic interfaces are set [17]. When implants are on the design stage, it is important to consider the degree of roughness of the sternal and intraosseous parts of the body and fixation elements [13]. The hypothesis that bioinert temporary constructions replacing bone defects prevent soft tissue constriction and are promising for atrophy, trauma, and post-cancer defects of the jaws has been presented for discussion [18]. In the presented clinical case, we relied on the fact of an almost complete absence of the oral vestibule after trauma and a significant lack of bone tissue in this area, which will not allow a full restoration of function and aesthetics. Also of great importance in making the decision was the patient's motivation and age - a young man and a physician.

5. Conclusions

In the presented case it is particularly important to remove the screws from the expander without breaking them. This is dictated by the possible positioning of dental implants in this area at the stage of subsequent autogenous augmentation. The possibility of wider use of additionally formed soft tissues and passive placement of the flap on the bone augmentation is realized. The possibilities of personalization of medical approaches in bone surgery allow making qualitative changes in the work of specialists and, most importantly, reducing the rehabilitation period and improving treatment results. In order to study the processes of reparative osteogenesis we analyzed micro preparations of peri-implantation zone tissues. As a result, the signs of osteo- and fibro-osteointegration were revealed. The obtained data are considered as a prerequisite for further clinical trials of the developed protocols of sequential replacement of jaw defects using 3D-printing.

Author Contributions: Conceptualization, V.P., D.S., and A.D.; methodology, D.U., M.G., and D.S.; validation, D.C., A.C., I.K. and M.G.; formal analysis, V.P.; investigation, E.B. and D.S.; data curation, I.K.; writing—original draft preparation, V.P., A.D. and D.C.; writing—review and editing, D.U., A.D. and D.G.; visualization, V.P. and V.A.; supervision, V.P., I.K., I.G.; project administration, V.P. All authors have read and agreed to the published version of the manuscript."

Informed Consent Statement: Informed consent was obtained from all subjects involved in the study.

Conflicts of Interest: The authors declare no conflict of interest.

References

1. Lee, C.C.; Hackenberg, B.; Halvorson, E.G.; Caterson, E.J. Vascularized treatment options for reconstruction of the ascending mandible with introduction of the femoral medial epicondyle free flap. *J Craniofac Surg.* 2014;25(5):1690-7.
2. Puricelli, E.; Chem, R.C. Thirty-eight-year follow-up of the first patient of mandibular reconstruction with free vascularized fibula flap. *Head Face Med.* 2021;17(1):46.
3. Schlund, M.; Nicot, R.; Depeyre, A.; Alkasbi, J.; Ferri, J. Reconstruction of a Large Posttraumatic Mandibular Defect Using Bone Tissue Engineering with Fresh-Frozen Humeral Allograft Seeded With Autologous Bone Marrow Aspirate and Vascularized With a Radial Forearm Flap. *J Craniofac Surg.* 2019;30(7):2085-2087.
4. Cricchio, G.; Lundgren, S. Donor site morbidity in two different approaches to anterior iliac crest bone harvesting. *Clin Implant Dent Relat Res.* 2003;5(3):161-9.
5. Quayle, A.A.; Marouf, H.; Holland, I. Alveolar ridge augmentation using a new design of inflatable tissue expander: surgical technique and preliminary results. *Br J Oral Maxillofac Surg.* 1990;28(6):375-82.
6. Wang, Y.; Zhang, S.; Nie, B.; Qu, X.; Yue, B. Approaches to Biofunctionalize Polyetheretherketone for Antibacterial: A Review. *Front Bioeng Biotechnol.* 2022;10:895288.
7. Darwich, K.; Ismail, M.B.; Al-Mozaiek, M.Y.A.; Alhelwani, A. Reconstruction of mandible using a computer-designed 3D-printed patient-specific titanium implant: a case report. *Oral Maxillofac Surg.* 2021;25(1):103-111.
8. Alexander Dolgalev, Igor Reshetov, Dmitry Svyatoslavov, Mikhail Sinelnikov, Konstantin Kudrin, Vladimir Dub, Vladimir Put, Vladimir Anikin. Experimental Biointegration of a Titanium Implant in Delayed Mandibular Reconstruction. *Journal of Personalized Medicine.* 2020;10(1): 6.
9. Shugaylov I., Moskovets O., Yudin D., Zinovjev I. Multimodal Anesthesia Using Xenon and Transcutaneous Electrical Nerve Stimulation During Dental Implantation. *International Journal of Engineering Trends and Technology.* 2020; 68(8):85-96.



10. Noelken, R.; Moergel, M.; Kunkel, M.; Wagner, W. Immediate and flapless implant insertion and provisionalization using autogenous bone grafts in the esthetic zone: 5-year results. *Clin Oral Implants Res.* 2018;29(3):320-327.
11. Noelken, R.; Moergel, M.; Pausch, T.; Kunkel, M. Clinical and esthetic outcome with immediate insertion and provisionalization with or without connective tissue grafting in the presence of mucogingival recessions: A retrospective analysis with follow-up between 1 and 8 years. *Clin Implant Dent Relat Res.* 2018;20(3):285-293.
12. Cabello, G.; Rioboo, M.; Fábrega, J.G. Immediate placement and restoration of implants in the aesthetic zone with a trimodal approach: soft tissue alterations and its relation to gingival biotype. *Clin Oral Implants Res.* 2013;24(10):1094-100.
13. Reshetov, I.V.; Samoilova, S.I.; Sukortseva, N.S.; Gaboyan, A.G.; Svyatoslavov, D.S.; Put, V.A.; Kudrin, K.G. In vivo modeling of a prefabricated cartilaginous autograft for reconstruction of the auricle in an experiment. *Head and Neck. Russian Journal.* 2020;8(1):8-14.
14. Put, V.A.; Solodkiy, V.G.; Reshetov, I.V.; Il'ichev, E.A.; Podstavnev, V.G. Implant-prosthetic rehabilitation of a patient with an extensive maxillofacial defect. *Stomatologia.* 2020; 99(5): 87-91.
15. Dragunova, S.G.; Kosyreva, T.F.; Khamidulin, G.V.; Shmaevsky, P.E.; Ermakova, N.V.; Severin, A.E.; Torshin, V.I.; Kastyro, I.V.; Scopich, A.A.; Gordeev, D.V.; Sedelnikova, A.D.; Kuznetsov, N.D.; Popadyuk, V.I.; Yudin, D.K. Assessment of the impact of closed sinus lifting on changes in the autonomic nervous system in the early postoperative period. *Head and neck. Russian Journal.* 2022;10(1):8-15.
16. Dragunova, S.G.; Reshetov, I.V.; Kosyreva, T.F.; Severin, A.E.; Khamidulin, G.V.; Shmaevsky, P.E.; Inozemtsev, A.N.; Popadyuk, V.I.; Kastyro, I.V.; Yudin, D.K.; Yunusov, T.Y.; Kleyman, V.K.; Bagdasaryan, V.V.; Alieva, S.I.; Chudov, R.V.; Kuznetsov, N.D.; Pinigina, I.V.; Skopich, A.A.; Kostyaeva, M.G. Comparison of the Effects of Septoplasty and Sinus Lifting Simulation in Rats on Changes in Heart Rate Variability. *Dokl Biochem Biophys.* 2021; 498(1):165169.
17. Dolgalev, A.A.; Trubushkina, E.M.; Kutsenko, A.P.; Dotdaeva, K.R.; Put, V.A.; Svyatoslavov, D.S.; Gladyshev, M.V.; Muraev, A.A. The method of the oroantral fistula treatment. *Head and neck. Russian journal.* 2022;10(2):41-48.
18. Martin, R.A.; Yue, S.; Hanna, J.V.; Lee, P.D.; Newport, R.J.; Smith, M.E.; Joned, J.R. Characterizing the hierarchical structures of bioactive sol-gel silicate glass and hybrid scaffolds for bone regeneration. *Philos Trans A Math Phys Eng Sci.* 2012; 370(1963):1422-43.

